

HAIR-LOSS SYNDROME IN BLACK-TAILED DEER OF THE PACIFIC NORTHWEST

Robert J. Bildfell,^{1,5} James W. Mertins,² Jack A. Mortenson,³ and Doug F. Cottam⁴

¹ Department of Biomedical Sciences, College of Veterinary Medicine, Oregon State University, 105 Magruder Hall, Corvallis, Oregon 97331, USA

² US Department of Agriculture—Animal and Plant Health Inspection Service, Veterinary Services, National Veterinary Services Laboratories, 1800 Dayton Road, Ames, Iowa 50010, USA

³ US Department of Agriculture—Animal and Plant Health Inspection Service, Veterinary Services, 530 Center St. NE #335, Salem, Oregon 97301, USA

⁴ Oregon Department of Fish and Wildlife, 2040 SE Marine Science Drive, Newport, Oregon 97365, USA

⁵ Corresponding author (email: Rob.Bildfell@oregonstate.edu)

ABSTRACT: A widespread hair-loss syndrome (HLS) has affected Columbian black-tailed deer (*Odocoileus hemionus columbianus*) in western Oregon and Washington (USA) since 1996. In order to better characterize the condition, 21 HLS-affected black-tailed deer (BTD) were necropsied, and body condition, parasite burdens, and significant lesions were noted. All deer were in poor body condition, and at least 17 had severe internal parasite burdens. A consistent finding was the presence of large numbers of chewing lice, identified as an indeterminate species of *Damalinia* (*Cervicola*). Four animals were infested with intrafollicular *Demodex* sp., the first report of this genus of mites in BTD. We postulate that the hair loss is largely due to ectoparasitism by a species of chewing louse that represents a new pathogen for BTD. This loss of pelage also may be an important contributor to the poor body condition of these animals.

Key words: Alopecia, Columbian black-tailed deer, *Damalinia* (*Cervicola*), *Demodex odocoilei*, hair loss, lice, *Odocoileus hemionus columbianus*, parasites, pediculosis.

INTRODUCTION

During 1995, biologists in Washington (USA) noticed an unusual syndrome of hair loss or “hair slip” in populations of Columbian black-tailed deer (BTD, *Odocoileus hemionus columbianus*). From an original nidus in west-central Washington, the condition spread throughout the western portion of the state, and by 1998 it also was observed in BTD populations west of the Cascade Mountains in Oregon (USA). Biologists, tribal elders, and hunters generally agreed that such a widespread and severe decrease in body condition and pelage of BTD was previously unknown in the region.

Animals with hair-loss syndrome (HLS) are usually thin or emaciated with loss of pelage over the thorax, flanks, and hind-quarters (Fig. 1). This loss of hair often is perceived first as a change in coat color, probably due to removal of outer guard hairs and thinning of hair coat. The pattern of hair loss is commonly asymmetric. If the condition progresses, animals may gain a “barbered” appearance as the hair

is groomed to short stubble. Eventually, bald patches of skin may develop. Deer with HLS may engage in excessive grooming or rubbing but otherwise remain alert and active. Severely affected deer may become progressively weaker and die. Conversely, some HLS deer have been observed to recover and regrow a normal hair coat.

Hair-loss syndrome affects BTD but has not yet been confirmed in mule deer (*Odocoileus hemionus hemionus*), a subspecies found primarily east of the Cascade Mountains. Hair-loss syndrome has not been reported in elk (*Cervus elaphus roosevelti*) sharing the same habitats with affected BTD.

Recorded sightings of HLS deer in Oregon during the past 5 yr indicate a distinct seasonality. Frequency is greatest in winter and spring, with few reports of HLS animals in summer or early fall. Affected deer populations include many seemingly healthy animals. Fawns and does are most often affected by HLS; mature bucks with HLS are seen infrequently. Deer between 6 mo and 12 mo of age



FIGURE 1. Juvenile deer with hair-loss syndrome. Note poor body condition and loss of hair over lateral trunk and rump.

seem especially prone to the condition. Estimates of the prevalence of HLS within different wildlife management units of the Oregon Department of Fish and Wildlife (ODFW) are confounded by variation between observers and by lack of a strict case definition. Spotlight surveys conducted in one unit during March–April of 2003 found 52.5% of observed deer ($n=221$) had some degree of hair loss (ODFW, unpubl. data). An average prevalence of 23.9% ($n=1,202$) across wildlife management units in northwest Oregon was observed in spring 2003. In 2000, estimates of the percentage of HLS-affected adult deer in various western Washington counties ranged from 0% to 60%, while the percentage of affected fawns ranged from 20% to 80% (Washington Department of Fish and Wildlife, 2001). Field observations by Oregon and Washington state biologists suggest that HLS occurs infrequently above 600 m elevation. Affected deer are seen in all major habitat types of western Oregon and Washington, including coastal bays, coastal mountains, central valley agricultural land, and urban areas.

MATERIALS AND METHODS

Twenty-one affected animals were submitted to the Oregon State University Veterinary Diagnostic Laboratory (Corvallis, Oregon, USA) for routine diagnostic evaluation between January 1999 and February 2003. Eleven animals were found dead by landowners. Ten deer showing representative signs of HLS were killed by biologists via gunshot. All animals were necropsied within 24 hr of death. One deer was collected in western Washington; the remainder originated in western Oregon (Tillamook, Lincoln, Polk, Linn, Benton, and Lane Counties).

Animals were identified as appropriate for the study based on the pattern of alopecia, poor body condition, and confirmation of death within the preceding 24 hr. Animals were classified as juvenile or adult based on body size, dentition, and antler growth. Internal or external lesions were noted.

Ectoparasites and sections of skin were collected and submitted to the National Veterinary Services Laboratories (NVSL, United States Department of Agriculture, Ames, Iowa, USA) for parasite identification. Our louse identifications follow the classification scheme of Lyal (1985). Sections of skin, each approximately 4 cm², were harvested from the dorsum, rump, muzzle, distal hind limb, shoulder, flank, groin, and proximal ear of three deer (numbers 17, 19, and 21) and fixed in 70% ethanol. Adult lice, nymphs, and nits within 1-cm² subsamples from these sections were subsequently counted under a dissecting microscope in order to estimate the distribution and intensity of lice infestation. Voucher specimens of lice are in the NVSL parasitology reference collection (accession numbers 86310, 215165, 217860, and 227557). Archived specimens of chewing lice collected from *O. hemionus* in the Pacific Northwest were borrowed from various collections for comparison with current louse specimens. Pertinent lice were from the US National Parasite Collection (US Department of Agriculture [USDA], Beltsville, Maryland, USA) and the Spencer Entomology Museum (University of British Columbia, Vancouver, British Columbia, Canada).

Feces from each carcass were analyzed by flotation (Whitlock, 1948) to obtain a crude estimate of the number of gastrointestinal parasites. Estimated counts were made of adult lungworms within major airways. Those animals with less than 50 intrabronchial worms were considered to have a low lungworm burden, whereas those with lungworm numbers greater than 50 were believed to have high-intensity infections. These ranges were based on

Kistner and Denney (1990). When summarizing surveys they performed during 1972–90, these researchers stated that 50 lungworms (*Dictyocaulus* sp.) was a typical parasite load in western Oregon deer. Adult lungworms collected from the bronchi of deer 18 and 20 were submitted to the US National Parasite Collection (voucher specimens 92710 and 92711) for identification using both morphologic and DNA probe methodologies (Jansen and Borgsteede, 1990; Divina et al., 2000).

Bacterial cultures of selected gross lesions were performed by inoculation of blood agar and McConkey's medium. Virus isolation was attempted on five animals (deer 1, 7–10). For each of these, samples of lung, kidney, lymph node, liver, and spleen were pooled, homogenized, and then inoculated onto a variety of cell culture monolayers, including BTB kidney, BTB testicle, bovine turbinate, and Vero (MARU) cells (Oregon State University Veterinary Diagnostic Laboratory and National Veterinary Sciences Laboratory, Ames, Iowa).

Various tissues were collected for histopathology (including at least skin and lung). Tissue samples were immersed in 10% formalin for at least 24 hr and then routinely processed for embedding in paraffin. Tissue sections (7 μ m thick) were subsequently stained with hematoxylin and eosin and examined microscopically.

RESULTS

Age, sex, date of collection, whether the animal was euthanized, and significant gross lesions are summarized in Table 1. Fourteen animals were emaciated, with no visceral or marrow fat. Seven others (deer 1–5, 13, 15) were in poor body condition with scant visceral fat. Four animals had evidence of diarrhea. All 18 juveniles had thymic atrophy, but subcutaneous lymph nodes were generally enlarged. Various internal lesions considered typical of BTB from these populations were omitted from Table 1 but were present in one or more animals each. Such findings included the presence of *Taenia* sp. cysticerci in the mesentery, *Setaria* sp. in the abdominal cavity, and *Cephenemyia* sp. larvae in retropharyngeal pouches. None of the subcutaneous abscesses observed in these animals was deemed clinically significant.

The degree of severity of hair loss ranged from mild thinning to locally ex-

tensive denuded areas. Irregularly shaped foci of erythema, 1–3 cm in diameter, were often visible in thinly haired areas such as the axilla, groin, perineum, and flanks. A few animals had foci of minor cutaneous excoriations. Louse counts from patches of shoulder/flank skin of six deer yielded a mean of 133 adults and nymphs per cm² (range=35–275) (Fig. 2). Even greater numbers of nits were present in many areas (Fig. 3). Tens to hundreds of thousands of lice were therefore estimated to be present on each animal except deer 12, which had only a few thousand lice. Topographic sampling of various sites on three deer revealed that the parasites occurred on every area of the body but were nearly absent on distal limbs. As anticipated, alopecic areas had fewer lice because chewing lice tend to attach primarily to hair shafts.

Representative lice from nine deer were identified as an unknown species of the chewing louse, *Damalinia* (*Cervicola*) (Lyal, 1985). Despite examination of thousands of these lice, no adult males were found. Other ectoparasites occasionally present in small numbers included hippoboscids (*Lipoptena depressa pacifica*) and fleas (*Pulex simulans*). A single tick was observed on one deer, but it was not submitted for identification.

Mites were found in hair follicles of four animals by histopathology. These mites were morphologically indistinguishable from *Demodex odocoilei*, a parasite of white-tailed deer (*Odocoileus virginianus*) (Desch and Nutting, 1974; Desch, pers. comm.). To our knowledge, *Demodex* have not been described previously in BTB. The species of *Damalinia* found on HLS deer was not found in any of the archival specimens examined. These archival specimens included the anticipated *Damalinia* (*Tricholipeurus*) *lipeuroides* and *Damalinia* (*Tricholipeurus*) *parallela* (Emerson et al., 1984), as well as samples of *Bovicola tibialis*, a species normally associated with Old World cervids (Lyal, 1985).

Results of fecal flotations are shown in

TABLE 1. Observations of black-tailed deer with hair-loss syndrome examined 1999–2003.

Deer No.	Collection date	Sex ^a	Age ^a	Found dead	Endoparasite eggs/g feces	Intrabronchial lungworms	Gross lesions
1	11 January 1999	M	J	N	25	<50	Single subcutaneous abscess
2	13 May 1999	M	J	N	148	<50	Focal arthritis, single subcutaneous abscess
3	6 April 2001	M	J	N	75	<50	None
4	10 April 2001	M	J	Y	400	>50	Multiple fractures, hit by car
5	31 August 2001	M	1 yr	N	375	>50	Lung abscessation
6	7 December 2001	F	J	Y	750	>50	Diarrhea
7	14 December 2001	M	J	Y	700	>50	Single healed rib fracture
8	9 January 2002	F	J	Y	100	<50	Minor subcutaneous hemorrhage over dorsum
9	10 January 2002	M	J	N	175	>50	Multiple subcutaneous abscesses, single renal infarct
10	23 January 2002	M	J	N	100	<50	Single subcutaneous abscess
11	25 January 2002	F	J	Y	825	<50	Single subcutaneous abscess
12	12 March 2002	F	J	Y	1,325	<50	Diarrhea
13	10 April 2002	M	3 yr	Y	75	<50	Acute dog attack wounds, chronic gunshot wounds, missing three incisors
14	25 November 2002	M	J	N	375	>50	Chronic ruminal ulcer, bacterial pneumonia, mycotic dermatitis of ears
15	17 December 2002	M	J	N	75	<50	None
16	14 January 2003	M	J	Y	1,000	>50	Diarrhea
17	14 January 2003	M	J	Y	350	>50	Single renal infarct
18	3 February 2003	M	J	Y	300	>50	None
19	4 February 2003	M	J	Y	2,625	>50	Diarrhea
20	4 March 2003	F	A	N	850	>50	Diarrhea, mummified fetus present
21	26 March 2003	M	J	N	400	<50	None

^a M = male, F = female, J = <1 yr-of-age, A = adult.




FIGURE 2. Heavy chewing louse infestation on head of deer 15. Only adult lice are easily seen in this photograph.

Table 1. The mean number of nematode eggs (all species) per gram of feces was 498 (range=25–2,625). Samples from five animals had coccidian oocysts (\bar{x} =218/g; range=50–2,175), and five had cestode eggs (\bar{x} =490/g; r =350–950).

The lungworms in major airways were identified morphologically as *Dictyocaulus eckerti*, which until recently has often been confused with *Dictyocaulus viviparus* (E. Hoberg, pers. comm.). This identification was confirmed by gene sequence analysis.

Streptococcus spp. was isolated from an arthritic joint and subcutaneous abscess (deer 2), *Escherichia coli* from lung abscesses (deer 5), and *Pasteurella multocida* from the pneumonic lung of deer 14. None of the virus isolation cultures yielded any growth.

Microscopic changes in skin sections from severe hair-loss areas typically included moderate epidermal thickening and orthokeratotic hyperkeratosis with only minor dermal inflammation. In more acutely affected areas, crusts of degenerate eosinophils and parakeratotic debris were also visible (Fig. 4). Foci of epidermal erosion or ulceration were accompanied by local accumulations of eosinophils and neutrophils. A perivascular to diffuse dermatitis with eosinophils, mast cells, neutrophils,

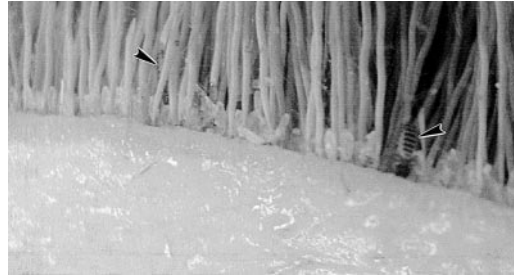


FIGURE 3. Skin piece from dorsum of deer 4. Although only two adult lice are visible (arrows), each nodule at the bases of hair shafts represents a nit.

and fewer lymphocytes and plasma cells was present in these acutely inflamed areas (Fig. 5). Although telogen and catagen phase hair follicles tended to predominate, anagen follicles also were visible. Adnexa were unremarkable. Multiple tangential sections of lice typically appeared on the skin surface (Fig. 4), where hair shafts still remained. In two juveniles (deer 3 and 14), multiple *Demodex* mites were in most follicles of multiple skin sections, accompanied by a mild lymphoplasmacytic perfolliculitis. Skin samples from the heads of deer 2 and 9 also contained a few intra-follicular mites but lacked any associated cellular response. Other less consistent

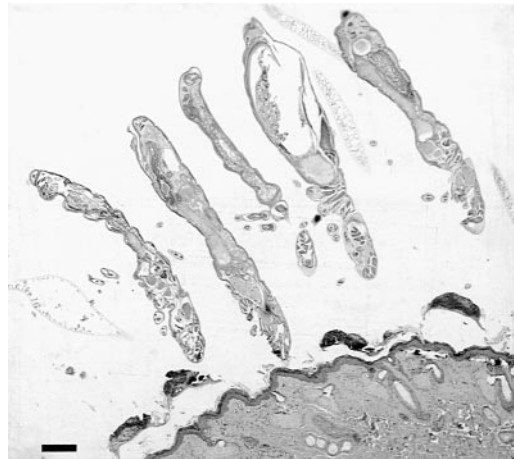


FIGURE 4. Histologic section from the flank skin of deer 19. Note the epidermal hyperplasia with hyperkeratosis plus multifocal eosinophilic and parakeratotic crusts (arrows). Tangential sections of chewing lice are visible on the skin surface. Bar=200 μ m.

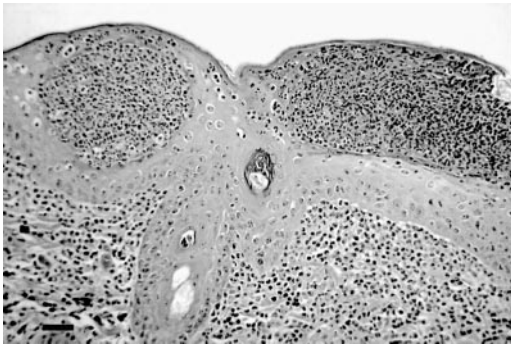


FIGURE 5. Histologic section of skin from the head of deer 8. Note severe leukocytic infiltrate in dermis and focus of erosion with leukocytic crust, as well as pustule formation in the acanthotic epidermis. Bar=40 μ m.

skin changes included foci of pyoderma (deer 3, 7, 8, and 14) and dermatophytosis (deer 9 and 14).

Lung sections often contained hyperplastic bronchiolar epithelium with intra-epithelial eosinophils and mild peribronchiolar lymphoid hyperplasia, characteristic of *Dictyocaulus* spp. infections (Dungworth, 1993). However, 90% of lung samples also contained randomly located granulomatous foci within the alveolar interstitium. This inflammatory response was directed at partially embryonated nematode eggs and larvae. In deer 1, a similar infiltrate rimmed nematode eggs in the subcapsular sinus of a prescapular lymph node. These findings are consistent with the lesions of *Parelaphostrongylus odocoilei*, an extrapulmonary lungworm (Pybus and Samuel, 1984; Lankester, 2001). The degree of pulmonary compromise associated with this component of verminous pneumonia was difficult to assess, but in some juveniles, more than one granuloma could be seen per 40 \times high-power field.

Sections of peripheral nerves (brachial plexus or sciatic nerve) often contained foci of perineuritis due to eosinophils, lymphocytes, and plasma cells, which is consistent with lesions attributed to *P. odocoilei* (Pybus and Samuel, 1984; Lankester, 2001). Peripheral lymph nodes were generally enlarged due to lymphoid follicular

hyperplasia and medullary plasmacytosis. Lymph node sinusoidal spaces often contained small numbers of eosinophils. Other microscopic lesions seen in more than one animal included intramuscular sarcocysts and mild multifocal lymphoplasmacytic interstitial nephritis.

DISCUSSION

The magnitude of this BTD HLS outbreak is unique. The wide distribution and diversity of deer populations affected by HLS argue against a nutritional or toxic cause. A florid infestation with chewing lice was one of the few consistent pathologic findings in HLS-affected deer, and pediculosis is a well-recognized cause of hair loss in wild mammals (Durden, 2001). Features such as the seasonality of the syndrome and a predilection for juveniles are typical of severe pediculosis (Yager and Scott, 1993; James, 1999; Durden, 2001). Chewing lice were the primary and consistent ectoparasites on HLS-affected deer, and their presence probably was the proximate cause of hair loss via stimulation of itching and excessive grooming. However, it is unusual to attribute such a widespread and severe disease syndrome solely to chewing lice, a group of organisms that is rarely implicated as a cause of serious disease in wildlife. Heavy infestations with chewing lice are often thought of as secondary consequences of immunosuppression or poor nutrition (Cowan, 1946; Durden, 2001). Concurrent infections with internal parasites may further compromise deer health. Although no control deer were available for this study and few normal "background" endoparasite burdens are established for this species, we suggest that at least 17 of the 21 animals examined suffered from a high level of endoparasitism (>100 egg/g feces and/or >50 adult lungworms). We further suggest that animals in poor body condition for whatever cause (e.g., endoparasitism, poor nutrition, intercurrent disease, etc.) will be more susceptible to ectoparasite infestations. Logically, the most debilitated animals are

likely to be most severely affected by a secondary problem, such as pediculosis. However, beyond these basic assumptions, questions remain about why HLS-affected deer are more obvious than similarly debilitated animals were during the past few decades and why such large number of deer have become affected over such a wide geographic range. At least eight of our deer were examined within a few hours of death, yet only small numbers of most other types of ectoparasites were found on them. Furthermore, we found only *Damalinia (Cervicola)* lice on afflicted deer. None of the other typical species of chewing and sucking lice found on deer in Oregon (Emerson et al., 1984) was present in samples, suggesting a specific susceptibility to *Damalinia (Cervicola)* sp. and perhaps competitive displacement of the normal louse fauna. A possible complicating factor arose in two fawns with demodecosis, a condition often linked to immunosuppression (Yager and Scott, 1993).

The key element in our hypothesis is that we believe the *Damalinia (Cervicola)* sp. we found on affected deer is not native to the Pacific Northwest and is thus a new parasite for BTB. All known species of *Damalinia (Cervicola)* occur only on deer and antelope in the Eastern Hemisphere (Lyal, 1987); none has been adequately and conclusively documented previously in the Americas. However, one of us has identified a similar or identical louse from white-tailed deer in several locations throughout the southeastern United States, (J. Mertins, unpubl. data). One potential route for introduction of this louse to North America is comingling of exotic and native cervids. Such parasite transfers have been recognized for several cervid parasites (Hoberg et al., 2001), and this phenomenon has been documented for a chewing louse infestation of BTB in California (Westrom et al., 1976). These authors found the exotic louse *B. tibialis* transferred from captive fallow deer (*Dama dama*) to BTB, and it predominated on the only animal coinfecting with both

native and exotic lice that was studied. The introduction of other nonnative lice to North America via importation of wild ungulates seems highly likely (Durden, 2001).

It is possible that *Damalinia (Cervicola)* sp. has been present but misidentified for some time in the Pacific Northwest. Published records of chewing lice on deer in the region are few (Hopkins, 1960; Walker and Becklund, 1970; Emerson et al., 1984) and difficult to confirm. Nevertheless, re-examination of a number of collections (Table 2) failed to find *Damalinia (Cervicola)* (J. Mertins, unpubl. data). Except for two mule deer, all hosts were BTB originating in insular or coastal areas of British Columbia or Oregon. Nearly all identified lice were the two typical chewing lice of deer from North America, *D. (T.) lipeuroides* or *D. (T.) parallela*.

However, three of the samples were *B. tibialis* (Table 2), the same louse found by Westrom in 1973 on BTB in California. As in California, the presence of Old World *B. tibialis* lice on BTB in southeastern British Columbia can be explained by cross-contamination from European fallow deer. Such deer were introduced to a few insular localities in southwestern British Columbia in the 1930s, including Vancouver and Salt Spring Islands (Nagorsen, 1990; Shackleton, 1999). The 1954 collection from Vancouver on the mainland was from a captive BTB that also may have been exposed to fallow deer (Hopkins, 1960). We have examined thousands of *Damalinia (Cervicola)* sp. lice from BTB (and other hosts) without finding any males. Although sex ratios in some species of *Damalinia (Cervicola)* are strongly female biased (Dobroruka, 1975; Lyal, 1985), this does not hold true for native *Damalinia (Tricholipeurus)* spp., in which males are always present in significant numbers (Marshall, 1981; Lyal, 1985), further supporting our identification of these lice as an exotic species. It is even possible that this unidentified *Damalinia* species is parthenogenetic, as is true for some spe-

TABLE 2. Chronologic listing of archival chewing louse collections from *Odocoileus hemionus* examined for this study.

Collection date	State/province ^a	Locality	Collector	Previous identification ^b	Correct identification ^b	Notes
22 May 1910	BC	Mt. Lehman (near Abbotsford)	S. Hadwen	DI	DI (2F, 2M)	c
29 February 1928	OR	Douglas County	J. N. Shaw/B. T. Simms	DI	DI (1F, 2N)	USNPC 028128
7 December 1929	BC	Howe Sound (north of Vancouver)	J. G. Spencer	DI	DI (1F, 1M)	BISH 22765 ^c
19 November 1933	BC	Vancouver Island	J. G. Spencer	DI	DI (6F)	BISH 22790 ^c
1 November 1935	BC	Queen Charlotte Islands	J. G. Spencer	None	DI (8F)	
18 February 1936	OR	Catherine Creek, Union County	D. F. Frewing	DI	DI (1M)	USNPC 41968
10 November 1938	BC	Victoria, Vancouver Island	I. McT. Cowan	DI	DI (1F, 1M)	
2 February 1941	BC	Salt Spring Island	I. McT. Cowan	Dl ^d	Bt (10F)	c
10 October 1942 ^e	BC	Duncan, Vancouver Island	J. G. Spencer	Dp	Dp (3F, 1M)	c
4 April 1943	BC	Hardy Island	J. G. Spencer	DI	DI (4f, 2M, 7N)	c
5 April 1943	BC	Barnet (near Vancouver)	J. G. Spencer	DI	DI (2F, 2M)	c
4 January 1945	BC	Pender Island	J. G. Spencer	DI	DI (2F)	
18 December 1947	BC	Cowichan Lake, Vancouver Island	I. McT. Cowan	DI	DI (1M)	c
December 1948	BC	Campbell River, Vancouver Island	J. G. Spencer	DI	Bt (1F)	
Spring 1950	BC	Vancouver	J. G. Spencer	None	DI (1F, 1M)	
5 February 1954	BC	Vancouver	J. G. Spencer	DI/Dts/Dts ^f	Bt (3F, 6N)	c
1 December 1964	BC	Chilliwack Lake (east of Vancouver)	J. G. Spencer	DI	DI (4F, 2M)	
12 December 1964	BC	Comox, Vancouver Island	J. G. Spencer	Dp	Dtu (10N)	
22 February 1965	BC	West Vancouver	J. G. Spencer	DI	DI (2F, 1M)	
22 January 1972	OR	Camp Adair, Benton County	None given	None	DI (1F, 3M)	NVSL 219750

^a BC = British Columbia; OR = Oregon.^b DI = *Damalinia (Tricholipeurus) lypeuroides*; Bt = *Bovicola tibialis*; Dp = *Damalinia (Tricholipeurus) parallela*; Dts = *Damalinia (Tricholipeurus) sp.*; Dtu = *Damalinia (Tricholipeurus) sp.*^c Collection cited in Hopkins (1960).^d On two slides, both of which also bear another unsigned identification label reading, "not *D. parallela* or *lypeuroides*."^e Collection date on slide label differs from that (10 May 1942) given by Hopkins (1960).^f Specimens on three separate slides; 1F, 2F, 6 nymphs. The 2F and nymphs were part of the series studied by Hopkins (1960) and designated by him as *D. (Tricholipeurus) sp.*, possibly new. The date on these slides is that of host's death 8 February 1954. The single F was identified/labeled by J. G. Spencer as *D. lypeuroides*.

cies of *Bovicola* lice, including *B. tibialis* (Westrom et al., 1976; Durden, 2001).

We are aware of only one published study of pediculosis in BTD. Cowan (1946) examined the health of 40 wild deer taken on southern Vancouver Island (British Columbia) and found that chewing lice were among the most universally present parasites. Cowan commented that thrifty deer supported small populations of lice, but unhealthy deer had heavy louse infestations, with all life stages distributed evenly over the long-haired regions of the body. He further described the physical condition and behavior of such deer in a manner that befits HLS. The lice were identified as an unspecified mixture of *D. (T.) lipeuroides* and *D. (T.) parallela*. Unfortunately, the accuracy of Cowan's results may be compromised by misidentification of at least some of his lice. We have examined some of Cowan's voucher specimens (Table 2), and specifically those from a Salt Spring Island BTD were the exotic louse, *B. tibialis*, and not *D. lipeuroides*. From the context and sparse details of Cowan's paper, one cannot positively determine how many of his louse collections may have been misidentified. Lice collected by J. G. Spencer (Table 2), which were also misidentified, confirm that *B. tibialis* was present on Vancouver Island during this time period. Thus, it is possible that some of the more severe cases of pediculosis reported by Cowan were actually caused by *B. tibialis*.

Another element of the pediculosis observations of Cowan (1946) that bears comparison to the present study is his characterization of louse densities. For an unstated number of hosts, he did counts of lice on five 6.54-cm² pieces of hide per animal. Furthermore, he estimated the approximate surface area of a small deer to be 6,542 cm². Cowan cites only the maximal mean louse density he encountered, 21.4 lice/cm², although he does not state whether these counts include nits. Thus, on two unspecified yearling deer in very poor condition, he observed a maximal in-

tensity of 140,000 lice per host animal. Whether the lice on these particular animals were the endemic or the extant exotic species cannot be determined from available evidence. Westrom et al. (1976) found a maximum of 8,200 *B. tibialis* lice on a BTD but did not comment on the health consequences of this pediculosis. However, other studies on the effects of *D. (T.) lipeuroides* and *D. (T.) parallela* on their hosts (primarily with respect to white-tailed deer) suggest that even substantial infestations (e.g., up to 70,550 lice/animal) may not be very pathogenic (Samuel and Trainer, 1971; Watson and Anderson, 1975; Samuel et al., 1980). Calculations like that of Cowan (1946), using the density counts (including nits) made on three BTD in the present study, yield intensities of 378,100, 1,243,900, and 1,493,600 lice per animal. Even discounting the observed nits, these animals sustained estimated infestations of 243,400, 308,100, and 738,600 lice per animal, respectively.

Introductions of parasites and pathogens to new host populations have become increasingly common due to changing patterns of human and animal movements, changes in husbandry practices, and continuing environmental disruptions (Hoberg, 1997; Brown, 1999). Naive species lack appropriate immune responses to these agents and often suffer devastating effects when exposed. We speculate that *Damalinia (Cervicola)* is an Old World louse that transferred from another species of cervid, but its primary host remains unknown. Many instances of inadvertent importation of ectoparasites on exotic wildlife have been documented, typically involving organisms much more visible than chewing lice (United States Animal Health Association, 1998). Heterospecific transfer of chewing lice is uncommon (Hopkins, 1949; Durden, 2001) because their entire life cycle is generally completed on the host. Nevertheless, disease resulting from the heterospecific transfer of both chewing and sucking lice to cervids

has been documented (Brunetti and Cribbs, 1971; Westrom et al., 1976; Foreyt et al., 1986). Chewing lice are generally not considered important pathogens of domestic or wild animals, principally because these parasites tend to feed superficially on hair, keratin, and surface secretions. It is also likely that a mutual accommodation has evolved between lice and their healthy, normal hosts. However, disease in cervids has resulted from severe infestations of sucking lice from other hosts (Brunetti and Cribbs, 1971; Foreyt et al., 1986). Poor health and decreased rate of gain have been associated with combined infestations of sucking and chewing lice in cattle (Kettle, 1974; Yager and Scott, 1993), and chewing lice are an important cause of decreased wool quality in sheep (Wilkinson et al., 1982; Yager and Scott, 1993; James, 1999). Ectoparasites are known to cause alopecia in various wildlife species. Winter tick syndrome in moose (*Alces alces*) results in debilitation, alopecia, and even death (McLaughlin and Addison, 1986). Sarcoptic mange is known to cause alopecia, loss of body condition, and death in a variety of species, including the chamois (*Rubicapra rubicapra*), ibex (*Capra ibex*), red fox (*Vulpes vulpes*), lynx (*Lynx lynx*), and others (Bornstein et al., 2001). The more serious mange outbreaks are generally associated with the exposure of a naive population, as we propose is the case for the Pacific Northwest BTD.

Some of the cutaneous lesions of HLS specimens are consistent with hypersensitivity, and such an inflammatory response could be a significant drain on the resources of affected deer. It is more likely that the indirect effects of pediculosis, such as decreased feeding time due to pruritis or decreased thermoregulatory ability due to hair loss, are key factors in the syndrome. Such consequences may be especially important to any BTD that have minimal energy reserves due to poor quality winter browse and to animals carrying large numbers of endoparasites.

The preponderance of juveniles in the

present study reflects field observations but also may be biased by the reluctance of biologists to euthanize does. The skewed sex ratio of studied animals (76% males) was unanticipated but may simply reflect the small sample size. Four of 21 HLS animals (deer 4, 5, 13, and 14) were affected by life-threatening disease processes other than parasitism/emaciation, and a further five had minor problems, such as subcutaneous abscesses or focal arthritis.

It is possible that HLS increases mortality and/or decreases fecundity in BTD populations, but appropriate studies are yet to be done. Annual counts of fawns per 100 does in one management district have revealed an association between the emergence of HLS and changes in population demographics. Fall counts dropped from 59 per 100 in 1996 (before HLS) to 39 per 100 in 2002. The corresponding spring surveys yielded a decline from 69 per 100 to 22 per 100 does (unpubl. data).

This louse probably can infest mule deer (*O. hemionus hemionus*), and experiments are planned to test this hypothesis. Efforts are also under way to determine the geographic range of the louse in both Oregon and Washington. Unless an immunosuppressive component is critical to the pathogenesis of HLS, some degree of effective host immune response should begin to develop in the BTD population over time. It will be interesting to observe whether this host-parasite relationship develops a less pathogenic equilibrium. The management implications of HLS await further field studies to determine whether HLS has a causal relationship with overall population numbers and age demographics.

ACKNOWLEDGMENTS

This study was funded by the Oregon Department of Fish and Wildlife and the USDA, Veterinary Services. The authors wish to thank the curators of the Spencer Entomology Museum and acknowledge E. P. Hoberg, A. Abrams, and staff of the US National Parasite Collection for loaning archival specimens of

lice and for assistance in the identification of *D. eckerti*. Our thanks to field biologists R. Green, T. Wagner, and W. High and to K. Fischer, J. Hicks, K. Needham, P. Pilitt, B. Sonn, and J. Robison for their excellent laboratory and technical assistance. Special thanks to C. Desch, B. Foreyt, and B. Hall for their help with this investigation.

LITERATURE CITED

- BORNSTEIN, S., T. MORNER, AND W. M. SAMUEL. 2001. *Sarcoptes scabiei* and sarcoptic mange. In Parasitic diseases of wild mammals, W. M. Samuel, M. J. Pybus, and A. A. Kocan (eds.). Iowa State University Press, Ames, Iowa, pp. 107–119.
- BROWN, C. 1999. Emerging diseases of animals. In Emerging infections, W. M. Scheld, W. A. Craig, and J. M. Hughes (eds.). ASM Press, Washington, D.C., pp. 153–163.
- BRUNETTI, O., AND H. CRIBBS. 1971. California deer deaths due to massive infestation by the louse (*Linognathus africanus*). California Fish and Game 57: 138–153.
- COWAN, I. M. 1946. Parasites, diseases, injuries, and anomalies of the Columbian black-tailed deer, *Odocoileus hemionus columbianus* (Richardson), in British Columbia. Canadian Journal of Research, Section D 24: 71–103.
- DESCH, C. F., AND W. B. NUTTING. 1974. *Demodex odocoilei* sp. nov. from the white-tailed deer, *Odocoileus virginianus*. Canadian Journal of Zoology 52: 735–739.
- DIVINA, B. P., E. WILHELMSSON, J. G. MATSSON, P. WALLER, AND J. HOGGLUND. 2000. Identification of *Dictyocaulus* spp. in ruminants by molecular and morphological analyses. Parasitology 121: 193–201.
- DOBROUKA, L. J. 1975. Wirtsrasen von *Cervicola meyeri* (Taschenberg, 1882) (Mallophaga: Trichodectidae). Věstník Československé Společnosti Zoologické 39: 251–253.
- DUNGWORTH, D. L. 1993. The respiratory system. In Pathology of domestic animals, Vol. 2. 4th Edition, K. V. F. Jubb, P. C. Kennedy, and N. C. Palmer (eds.). Academic Press Inc., San Diego, California, pp. 677–680.
- DURDEN, L. 2001. Lice (Phthiraptera). In Parasitic diseases of wild mammals, W. M. Samuel, M. J. Pybus, and A. A. Kocan (eds.). Iowa State University Press, Ames, Iowa, pp. 3–17.
- EMERSON, K. C., C. MASER, AND J. O. WHITAKER, JR. 1984. Lice (Mallophaga and Anoplura) from mammals of Oregon. Northwest Science 58: 153–161.
- FOREYT, W. J., D. H. RICE, AND K. C. KIM. 1986. Pediculosis of mule deer and white-tailed deer fawns in captivity. Journal of the American Veterinary Medical Association 189: 1172–1173.
- HOBERG, E. P. 1997. Parasite diversity and emerging pathogens: A role for systematics in limiting impacts on genetic resources. In Global genetic resources: Access, ownership and intellectual property rights, K. E. Hoagland and A. Y. Rossman (eds.). Association of Systematics Collections, Washington, D.C., pp. 71–83.
- , A. A. KOCAN, AND L. G. RICKARD. 2001. Gastrointestinal strongyles in wild ruminants. In Parasitic diseases of wild mammals, W. M. Samuel, M. J. Pybus, and A. A. Kocan (eds.). Iowa State University Press, Ames, Iowa, pp. 193–227.
- HOPKINS, G. H. E. 1949. The host-associations of the lice of mammals. Proceedings of the Zoological Society of London 119: 387–604.
- . 1960. Notes on some Mallophaga from mammals. Bulletin of the British Museum of Natural History (Entomology) 10: 77–99.
- JAMES, P. J. 1999. Do sheep regulate the size of their mallophagan louse populations? International Journal for Parasitology 29: 869–875.
- JANSEN, J., AND F. H. BORGSTEEDE. 1990. *Dictyocaulus* species, lungworms in cattle and deer in The Netherlands. Tijdschrift voor Diergeneeskunde 115: 155–158.
- KETTLE, P. R. 1974. The influence of cattle lice (*Damalinia bovis* and *Linognathus vituli*) on weight gain in beef animals. New Zealand Veterinary Journal 22: 10–11.
- KISTNER, T. P., AND S. R. DENNEY. 1990. Final report to Oregon Department of Fish and Wildlife, Columbia white tailed deer study, Douglas County, Oregon.
- LANKESTER, M. W. 2001. Extrapulmonary lungworms of cervids. In Parasitic diseases of wild mammals, W. M. Samuel, M. J. Pybus, and A. A. Kocan (eds.). Iowa State University Press, Ames, Iowa, pp. 228–278.
- LYAL, C. H. C. 1985. A cladistic analysis and classification of trichodectid mammal lice (Phthiraptera: Ischnocera). Bulletin of the British Museum of Natural History (Entomology) 51: 187–346.
- . 1987. Co-evolution of trichodectid lice (Insecta: Phthiraptera) and their mammalian hosts. Journal of Natural History 21: 1–28.
- MARSHALL, A. G. 1981. The sex ratio of ectoparasitic insects. Ecological Entomology 6: 155–174.
- MCLAUGHLIN, R. F., AND E. M. ADDISON. 1986. Tick (*Dermacentor albipictus*)-induced winter hair-loss in captive moose (*Alces alces*) Journal of Wildlife Diseases 22: 502–510.
- NAGORSEN, D. 1990. The mammals of British Columbia: A taxonomic catalogue. Royal British Columbia Museum Memoirs 41: 1–148.
- PYBUS, M. J., AND W. M. SAMUEL. 1984. Lesions caused by *Parelaphostrongylus odocoilei* (Nematoda: Metastrongyloidea) in two cervid hosts. Veterinary Pathology 21: 425–431.
- SAMUEL, W. M., AND D. O. TRAINER. 1971. Seasonal fluctuations of *Tricholipeurus parallelus* (Osborn,

- 1896) (Mallophaga: Trichodectidae) on white-tailed deer (*Odocoileus virginianus* [Zimmermann, 1780]) from South Texas. *American Midland Naturalist* 85: 507–513.
- , E. R. GRINNELL, AND A. J. KENNEDY. 1980. Ectoparasites (Mallophaga, Anoplura, Acari) on mule deer, *Odocoileus hemionus*, and white-tailed deer, *Odocoileus virginianus*, of Alberta, Canada. *Journal of Medical Entomology* 17: 15–17.
- SHACKLETON, D. 1999. Hoofed mammals of British Columbia. University of British Columbia Press/Royal British Columbia Museum, Vancouver, British Columbia, Canada, 268 pp.
- UNITED STATES ANIMAL HEALTH ASSOCIATION. 1998. Foreign pests and vectors of arthropod-borne diseases. In *Foreign animal diseases*, Carter Printing Company, Richmond, Virginia, pp. 225–224.
- WALKER, M. L., AND W. W. BECKLUND. 1970. Checklist of the internal and external parasites of deer, *Odocoileus hemionus* and *O. virginianus*, in the United States and Canada. Index-Catalog of Medical and Veterinary Zoology, Special Publication 1: 1–45.
- WASHINGTON DEPARTMENT OF FISH AND WILDLIFE. 2001. Hair Loss Syndrome: Region 5. Vancouver, Washington, pp. 1–4.
- WATSON, T. G., AND R. C. ANDERSON. 1975. Seasonal changes in louse populations on white-tailed deer (*Odocoileus virginianus*). *Canadian Journal of Zoology* 53: 1047–1054.
- WESTROM, D. R., B. C. NELSON, AND G. E. CONNOLLY. 1976. Transfer of *Bovicola tibialis* (Piaget) (Mallophaga: Trichodectidae) from the introduced fallow deer to the Columbian black-tailed deer in California. *Journal of Medical Entomology* 13: 169–173.
- WHITLOCK, H. V. 1948. Some modifications of the McMaster helminth egg-counting technique and apparatus. *Australian Council of Scientific and Industrial Research* 21: 177–180.
- WILKINSON, F. C., C. G. CHANEET, AND B. R. BEETSON. 1982. Growth of populations of lice, *Damalinia ovis*, on sheep and their effects on production and processing performance of wool. *Veterinary Parasitology* 9: 243–252.
- YAGER, J. A., AND D. W. SCOTT. 1993. The skin and appendages. In *Pathology of domestic animals*, Vol. 1. 4th Edition, K. V. F. Jubb, P. C. Kennedy, and N. C. Palmer (eds.). Academic Press Inc., San Diego, California, pp. 679–688.

Received for publication 9 October 2003.